

RESEARCH PAPER

Body image distortions following spinal cord injury

Christina T Fuentes,¹ Mariella Pazzaglia,^{2,3} Matthew R Longo,⁴ Giorgio Scivoletto,³ Patrick Haggard¹¹Institute of Cognitive Neuroscience, University College London, London, UK²Dipartimento di Psicologia, Università degli Studi di Roma, Rome, Italy³Istituto di Ricovero e Cura a Carattere Scientifico, Fondazione Santa Lucia, Rome, Italy⁴Department of Psychological Sciences, Birkbeck, University of London, London, UK**Correspondence to**Dr C T Fuentes, Institute of Cognitive Neuroscience, University College London, 17 Queen Square, London WC1N 3AR, UK; c.fuentes@ucl.ac.uk

Received 23 August 2012

Revised 30 October 2012

Accepted 2 November 2012

Published Online First

1 December 2012

ABSTRACT**Background** Following spinal cord injury (SCI) or anaesthesia, people may continue to experience feelings of the size, shape and posture of their body, suggesting that the conscious body image is not fully determined by immediate sensory signals. How this body image is affected by changes in sensory inputs from, and motor outputs to, the body remains unclear.**Methods** We tested paraplegic and tetraplegic SCI patients on a task that yields quantitative measures of body image. Participants were presented with an anchoring stimulus on a computer screen and told to imagine that the displayed body part was part of a standing mirror image of themselves. They then identified the position on the screen, relative to the anchor, where each of several parts of their body would be located. Veridical body dimensions were identified based on measurements and photographs of participants.**Results** Compared with age matched controls, paraplegic and tetraplegic patients alike perceived their torso and limbs as elongated relative to their body width. No effects of lesion level were found.**Conclusions** The common distortions in body image across patient groups, despite differing SCI levels, imply that a body image may be maintained despite chronic sensory and motor loss. Systematic alterations in body image follow SCI although our results suggest these may reflect changes in body posture, rather than loss of specific sensorimotor pathways. These findings provide new insight into how the body image is maintained, and may prove useful in treatments that intervene to manipulate the body image.**INTRODUCTION**In order to interpret sensory information and interact with our environment, the brain requires a model of the body that represents body part size, shape and configuration. This representation of the body can be thought of as a conscious 'body image' and reflects what the body is perceived to be like.¹ Note that use of this term in the scientific literature need not include the emotional and aesthetic elements associated with it in everyday use, and in some psychological traditions.² It remains unclear how sensory and motor information contributes to our conscious body image.Studying the effects of sensory loss on body representations can reveal the role played by afferent information in the body image. Following damage to the spinal cord or anaesthesia, affected body parts are not perceived as having vanished. Rather, vivid 'phantom' experiences can be maintained.³⁻⁶ In paraplegia, patients commonly report feelings that their body feels larger than actualsize.³⁻⁵ Similar results have been found following acute deafferentation: anaesthetising digits in healthy adults results in increased perceived size of the digit.^{7,8} On the other hand, the perception of phantom limbs (ie, the presence of the missing limb) after traumatic amputation often results in shrinkage and telescoping of the perceived limb.^{9,10} Studying patients with spinal cord injuries may help clarify these conflicting findings.Spinal cord injury (SCI) patients present with loss of motor and sensory functions below the level of injury, with the extent of loss depending on the degree of tissue damage. SCI patients therefore provide important insight into the effects of sensorimotor loss on one's body image. Moreover, functional and structural cortical reorganisation following SCI¹¹⁻¹⁵ provides a method of investigating the relation between neural plasticity and conscious body image.Almost five decades ago, a study demonstrated that paraplegic patients (PPP) overestimate their shoulder width.¹⁶ Conomy⁴ continued the study of body image in SCI a decade later by qualitatively assessing disturbances in patients. In addition to disturbances in limb position, posture and movement, seven of the 18 SCI patients, including tetraplegic (cervical lesion) and paraplegic (thoracic lesions) patients, reported changes in body component size, specifically increased foot and leg size. These assessments, however, were not quantified, and it is unclear whether the disorders were directly due to sensorimotor loss or to some secondary factor, such as immobilisation. A later study indicated only slight differences in body size estimates between individuals with acquired (SCI) and congenital (cerebral palsy) motor impairments.¹⁷

A more thorough assessment of body image in SCI patients could provide insight into how body image depends on sensorimotor information, and what distortions may result from an absence of afferent signals. Moreover, assessing body image following SCI can provide insight into the brain areas that are involved in forming and maintaining the body image. Here we apply a new quantitative test of body image in wheelchair bound PPP and tetraplegic patients (TPP) to establish what distortions are present, and how they relate to the level of injury.

METHODS**Participants**

Forty-two participants took part in the study: 12 PPPs (one woman, 39.8±11.0 years), 12 TPP (one woman, 36.3±13.1 years) and 18 healthy controls (CTL, one woman, 42.5±11.1 years). The three

Spinal cord injury

groups did not differ in age or level of education. Table 1 contains clinical information for the patient groups. Informed written consent was obtained for all procedures, and the study was approved by the ethics committee of Santa Lucia Hospital, Rome, Italy.

For SCI patients, the neurological injury level was determined using the American Spinal Injury Association standards for classification of SCI.¹⁸ Each patient was examined by an expert neurologist (GS), and a standardised American Spinal Injury Association protocol was used to determine the most caudal level of the spinal cord with normal sensory and motor function on both sides of the body (table 1). All patients were manual wheelchair users and were recruited from physiotherapy programmes for patients with SCI. No patient had suffered a head or brain lesion, as documented by conventional clinical CT or MRI scans.

Body image task (BIT)

Procedure

The task was based on a concept developed by Daurat-Hmeljiak *et al*,¹⁹ with a number of extensions. Participants were seated in front of a table with a 10.4 inch touch screen monitor. A researcher explained that during the task they would see either the outline of a head near the top of the screen or the outline of a left or right foot near the bottom of the screen ('anchors', see figure 1). Participants were instructed to imagine that they were looking at a mirror image of themselves standing with their arms at their sides; a researcher briefly demonstrated this position to each participant. Participants were told to scale the imagined picture of themselves such that the size of their head or the size of their foot matched the size of the displayed

anchor on the screen. The name of a body part to be placed on that trial was displayed on the screen for 3 s, after which one of the anchor stimuli was displayed at one of four random positions on the screen (one of four positions near the top of the screen for the head anchor and one of four positions near the bottom for the foot anchors, figure 1). Participants used a stylus to tap the screen where they thought the named body part would be located on their image of their own body in the canonical position, relative to the displayed anchor. Participants were given 4 s to respond before the next trial began.

Participants identified the location of 14 body parts (13 per anchor): head (for right and left foot anchor blocks), left shoulder, right shoulder, left elbow, right elbow, left hand, right hand, left hip, right hip, navel, left knee, right knee, left foot (for head and right foot anchor blocks) and right foot (for head and left foot anchor blocks). Trials were blocked by anchor. There were two blocks for each of the three anchors. The first three blocks were presented in random order and the subsequent three were given in the mirror order. Each body part was repeated four times per block in a pseudo random order for a total of eight trials per body part, per anchor.

A researcher identified the 14 body parts that were to be tested during the task by pointing to their location on herself during the initial demonstration of the test position. Participants completed a three trial practice with the head anchor and a three trial practice with the right foot anchor before starting the experiment.

Analysis

We calculated the average reported position of each body part, for each anchor. Responses that clearly confounded the left

Table 1 Patient information

| Group | Sex | Age (years) | Time since injury (years) | Aetiology | Lesion level | AIS grade | Motor level | | Sensory level | |
|-------|-----|-------------|---------------------------|-----------|--------------|-----------|-------------|------|---------------|------|
| | | | | | | | Right | Left | Right | Left |
| PPP1 | M | 36 | 0.5 | T | T3 | A | T3 | T3 | T3 | T3 |
| PPP2 | F | 49 | 0.5 | T | T12 | A | T12 | T12 | T12 | T12 |
| PPP3 | M | 42 | 2.2 | T | T10 | A | T10 | T10 | T10 | T10 |
| PPP4 | M | 44 | 16.0 | T | T5 | A | T5 | T5 | T5 | T5 |
| PPP5 | M | 42 | 2.8 | T | T3 | A | T3 | T3 | T3 | T3 |
| PPP6 | M | 38 | 15.0 | T | T8 | A | T8 | T8 | T8 | T8 |
| PPP7 | M | 38 | 5.0 | T | T12 | A | T12 | T12 | T12 | T12 |
| PPP8 | M | 38 | 13.0 | T | T8 | A | T8 | T8 | T8 | T8 |
| PPP9 | M | 41 | 4.0 | N | T9 | A | T9 | T9 | T6 | T9 |
| PPP10 | M | 19 | 1.5 | T | T10 | A | T10 | T10 | T10 | T10 |
| PPP11 | M | 56 | 26.0 | T | T5 | A | T5 | T5 | T5 | T5 |
| PPP12 | M | 35 | 1.0 | T | T10 | A | T11 | T11 | T11 | T11 |
| TPP1 | M | 27 | 0.4 | T | C6 | B | T1 | T1 | + | + |
| TPP2 | M | 55 | 0.6 | T | C6 | B | T8 | T8 | + | + |
| TPP3 | M | 47 | 3.1 | N | C8 | D | T1 | T1 | + | + |
| TPP4 | M | 63 | 0.5 | T | C6 | A | C6 | C6 | T7 | T7 |
| TPP5 | M | 40 | 2.7 | T | C5 | A | C5 | C5 | C4 | C4 |
| TPP6 | M | 22 | 0.9 | T | C7 | D | C6 | C5 | C7 | C7 |
| TPP7 | M | 22 | 1.2 | T | C6 | A | C6 | C6 | C6 | C6 |
| TPP8 | F | 29 | 2.0 | T | C6 | C | C7 | C6 | + | + |
| TPP9 | M | 30 | 11.0 | T | C5 | A | C6 | C6 | C5 | C5 |
| TPP10 | M | 29 | 11.0 | T | C6 | C | C6 | C6 | C8 | C8 |
| TPP11 | M | 41 | 10.0 | T | C6 | A | C6 | C6 | C8 | C8 |
| TPP12 | M | 31 | 1.5 | T | C6 | A | C6 | C6 | C6 | C6 |

+, conserved function, AIS, Abbreviated Injury Scale; N, neoplastic; PPP, paraplegic patient; T, traumatic; TPP, tetraplegic patient.




Figure 1 Example response screens of BIT. On a given trial, participants had to identify the position of a previously specified body part relative to a displayed anchor body part. Participants were instructed to imagine they were looking at a standing mirror image of themselves scaled such that the size of their head or the size of their foot matched the size of the displayed anchor. They then tapped the screen to denote body part locations. Trials were blocked based on anchor type. BIT, body image task.

and right sides of the body or were beyond 2 SDs of the participant's mean were excluded from analysis. On average, 5% of trials per participant were excluded.

For our first analysis, we compared all body part lengths across groups. Average reported body part positions were transformed into a common space by expressing them as a proportion of judged height (y, distance from head to feet).²⁰ This allowed for comparisons of the relative lengths of different body parts across anchors and participants. Examples of the body image based on this common space are shown in figure 3. The following body part lengths were then calculated:

- ▶ Head to left and right shoulder
- ▶ Head to navel
- ▶ Shoulder width (left shoulder to right shoulder)
- ▶ Upper arm length (shoulder to elbow), left and right
- ▶ Lower arm length (elbow to hand), left and right
- ▶ Total arm length (shoulder to hand), left and right
- ▶ Torso length (shoulder to hip), left and right
- ▶ Navel to hip, left and right
- ▶ Hip width (left hip to right hip)
- ▶ Upper leg length (hip to knee), left and right
- ▶ Lower leg length (knee to foot), left and right
- ▶ Total leg length (hip to foot), left and right

All lengths were then expressed as the difference between the perceived length and the participant's true body part length, as a proportion of the true length. We performed a repeated measures ANOVA with body parts ($n=21$) and anchor ($n=3$) as within group factors and group ($n=3$) as a between group factor.

In a second analysis we compared body aspect ratios. We calculated the following three ratios for each participant, for each anchor: torso length/hip width, arm length/shoulder width and leg length/hip width. Ratios were then expressed as the difference between the perceived ratio and the participant's true ratio, as a proportion of the true ratio. Thus ratios of 0 represent accurate perception of true body aspect. Ratios >0 represent perceived elongation of the torso, arms or legs relative to perceived body width, while ratios <0 represent perceived shortening of the torso, arms or legs relative to perceived body width. We performed a repeated measures ANOVA with these body aspect ratios ($n=3$) and anchor ($n=3$) as within group factors and group ($n=3$) as a between group factor.

Template selection task

Procedure

In this task, participants identified which of a range of visually presented body shapes corresponded most closely to the perceived shape of their own body. Based on the true dimensions of 18 CTL participants (not included in this dataset), a figure with a hip width/height ratio of 0.177 was created, with a dot marking the location of each body part identified in the body image task (BIT). The width of the figure was altered to create 13 templates with widths ranging from 40% to 160% of the original, average width, in increments of 10%.

After completion of the BIT, participants performed the template selection task, based on these width altered templates. On each trial, nine of these figures were placed side by side in order of increasing width (figure 2). Participants were instructed

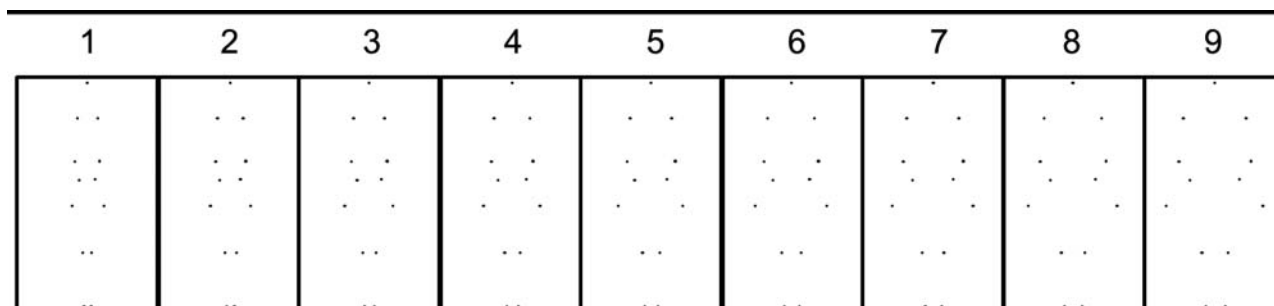


Figure 2 Example trial of template selection task. On the template selection task, participants selected which figure most closely matched their body shape from a series of templates with differing widths. In this example trial, templates start at a width/height ratio of 0.07 (template 1) and increase to a ratio of 0.21 (template 9).

Spinal cord injury

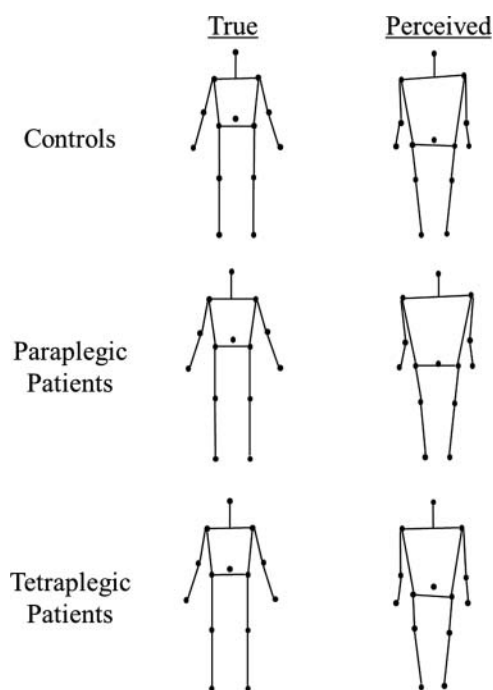


Figure 3 Average compiled body images. The left column depicts the average true configuration of participants' body parts for each group. In the right column are the average perceived representations (averaged across anchors). These figures are provided as a means to qualitatively appreciate the difference between the body image and true body dimensions. All analyses were done on values that were normalised by each participant's true body dimensions, which are not depicted here.

to select the figure they felt most closely matched their body shape. There were a total of nine trials, each with a different starting figure, and trials were presented in a random order.

Analysis

For each participant, the hip width/height ratio of each template selected was averaged across the nine trials. This averaged template ratio was compared with the participant's true hip width/height ratio. Differences between true ratios and average selected template ratios were compared across groups.

Participants' true body dimensions

We took the following measurements from each participant, in order to compare the perceived positions of body parts with their actual positions relative to each other:

- ▶ Left shoulder to right shoulder
- ▶ Right shoulder to right elbow
- ▶ Right elbow to centre of palm of right hand
- ▶ Right shoulder to right pelvic bone
- ▶ Left pelvic bone to right pelvic bone
- ▶ Navel to right pelvic bone (participants pointed to their navel position over their shirt)
- ▶ Right pelvic bone to right kneecap
- ▶ Right kneecap to heel of right foot

To better compare the wheelchair bound patients with CTL subjects, all body measures were taken using measuring tape while the participant was seated. In addition, a front view photograph of participants was taken while participants were seated with their arms outstretched at their sides to confirm measurements.

RESULTS

By comparing perceived body part lengths across groups with differing SCI levels, we aimed to establish the effect of sensori-motor loss on body image. Figure 3 shows each group's average body image compared with their average true body configurations. When averaged across participants, body images were similar across groups. While qualitatively interesting, these average images can be misleading because in order to properly test for group differences, individual distortions must be taken into account. All analyses were therefore performed on perceived body part lengths expressed as the difference between the perceived length and the participant's true body part length, as a proportion of the true length.

The normalised perceived length of 21 body parts was calculated (see methods). A repeated measures ANOVA with anchor ($n=3$) and body part ($n=21$) as within group factors and group ($n=3$) as a between group factor revealed a trend towards an effect of group ($F(2,39)=2.53$, $p=0.09$). Overall, perceived body part length relative to height was smallest in TPP (0.09), slightly greater in PPP (0.13) and greatest in the CTL group (0.18).

ANOVA revealed a body part \times group interaction ($F(40,780)=1.50$, $p=0.03$). Post hoc t tests showed that this interaction was driven by group differences in shoulder width and hip width. TPP perceived their shoulder and hip widths as narrower than the CTL group (both $p<0.01$; TPP shoulder 0.37, hip 0.18; CTL 0.69 and 0.62)—that is, their body image was elongated compared with the CTL group. PPP fell between the other two groups for both widths (shoulder 0.55, hip 0.36, all $p>0.10$). ANOVA revealed no effect of anchor ($F(2,78)=0.80$, $p=0.46$), no anchor \times group interaction ($F(4,78)=0.55$, $p=0.70$) and no three way factor interaction ($F(80,1560)=1.22$, $p=0.10$).

The first analysis revealed group differences in body width relative to height, with no consistent differences in perceived limb length or torso length. However, because expressing body part lengths as a proportion of height could mask elongation effects, we further investigated distortions in body image across groups by comparing body aspect ratios. Specifically, we calculated the following three body aspect ratios for each participant, for each anchor: torso length/hip width, arm length/shoulder width and leg length/hip width. Ratios were then expressed as the difference between the perceived ratio and the participant's true ratio, as a proportion of the true ratio. A repeated measures ANOVA with these body aspect

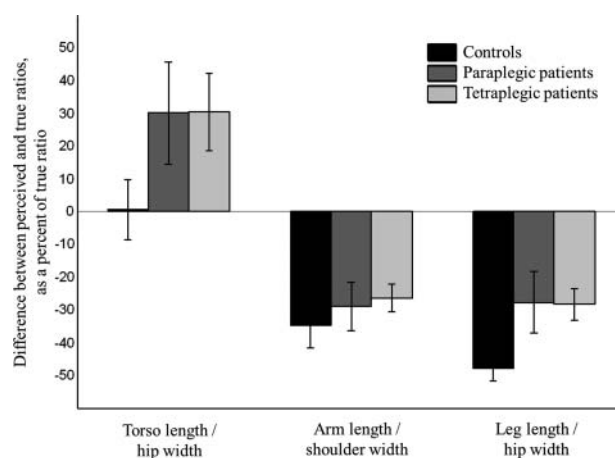


Figure 4 Perceived body aspect ratios. There was an overall effect of elongation relative to width for the paraplegic and tetraplegic patient groups compared to the control group.

ratios ($n=3$) and anchor ($n=3$) as within group factors and group ($n=3$) as a between group factor revealed a main effect of group ($F(2,39)=3.38$, $p=0.04$). Fisher's least significant difference test revealed that both paraplegic and tetraplegic groups had overall significantly greater ratios than the CTL group (CTL -0.27 , PPP -0.09 , TPP -0.08 ; PPP vs CTL, $p=0.04$; TPP vs CTL, $p=0.03$). The two patient groups did not differ from each other ($p=0.94$). Crucially, there was no interaction between ratio and group ($F(4,78)=1.87$, $p=0.12$), indicating that both PPP and TPP overestimated all ratios relative to CTL (figure 4). This demonstrates a general perceived elongation of the body and limbs, relative to perceived width, in SCI patients relative to the CTL group.

There was also an effect of ratio ($F(2,78)=106.02$, $p<0.01$), with torso ratios on average overestimated relative to both arm and leg ratios (post hoc *t* test torso vs arm, $p<0.01$; torso vs leg, $p<0.01$), and leg ratios slightly underestimated relative to arm ratios (arm vs leg, $p=0.04$). There was neither an effect of anchor ($F(2,78)=0.14$, $p=0.87$) nor an interaction of anchor with group ($F(4,78)=0.66$, $p=0.62$) or ratio ($F(4,78)=1.66$, $p=0.16$). There was no three way factor interaction ($F(8,156)=0.56$, $p=0.81$).

Because not all patients had complete lesions, we repeated the ANOVA including only patients with Abbreviated Injury Scale (AIS) grade A lesions ($n=18$), collapsing patients across SCI groups. This group ($n=2$) by anchor ($n=3$) by ratio ($n=3$) ANOVA revealed the same crucial result as the analysis that included grade B, C and D lesion patients: a main effect of group ($F(1,34)=6.25$, $p=0.02$), with the SCI group showing greater ratios than the CTL group.

To test whether distortions in body aspect ratios were significantly different to true body distortions and not just different across groups, we compared true body aspect ratios to perceived ratios (collapsing across anchors since there were no effects or interactions of anchors in previous analyses). Paired *t* tests revealed no difference between true and perceived torso ratios for CTL ($p=0.77$), but overestimation for TPP ($p<0.01$) and a trend toward overestimation for PPP ($p=0.07$). For arm and leg ratios, all groups showed significant underestimation of perceived ratios compared with true (all $p<0.01$).

To ensure that our effects were independent of lesion level and time since injury, we ran a final set of analyses in which all SCI patients were grouped together. Across all SCI patients, neither lesion level nor time since injury correlated with any of the body aspect ratios (all $p>0.15$).

When presented with a series of body templates with differing hip width/height ratios, participants in all three groups performed well at selecting the templates that most closely matched their true body dimensions (average difference between template ratio and true ratio: CTL 0.012, PPP 0.006, TPP 0.011). A 3×1 ANOVA revealed no main effect of group ($F(2,41)=0.88$, $p=0.43$). This demonstrates that despite the implicit distortions in the perceived relative length and width of their bodies revealed in the BIT, the PPP and TPP body images were overall as accurate as the CTL group when tested in a task involving recognition of a complete visual body—that is, template matching.

DISCUSSION

We have developed a novel, quantitative test of body image—the BIT. This test involves identifying the position of one body part relative to another body part (an anchor), based on the perceived relative positions of the body parts on one's own body as if seen in a canonical view. We used the BIT to

compare the perceived length of intact versus affected body parts in SCI patients compared with age matched CTL. We found that regardless of differing SCI levels, compared with CTL, PPP and TPP alike implicitly perceive their torso and limbs as elongated relative to their body width. If body image depended strongly on sensorimotor signals, as suggested by experimental anaesthesia studies^{7 8} and amputation studies,^{9 10} then an effect of lesion level might be predicted. However, no such effect was found. Thus our results suggest that chronic sensorimotor loss may not directly or specifically alter individual elements of body image. In contrast, the global elongation of body image that we observed in SCI patients, both above and below the lesion level, could be a secondary consequence of prolonged changes in body posture, perhaps reflecting an inability to stand or walk.¹⁶

Several studies have demonstrated that functional and structural cortical reorganisation occur following deafferentation.^{11–15} In SCI it appears that cortical reorganisation is particularly associated with the growth of new intracortical connections.^{13 21} Henderson *et al*¹⁵ found that primary somatosensory cortex (S1) reorganisation of the hand area towards the deafferented leg area following SCI was associated with grey matter preservation and decreased fractional anisotropy. These changes in cortical organisation may occur secondary to altered spinothalamic and spinocerebellar input and presumably reflect the adaptation of cortical maps to altered inputs.¹¹

Although sensory information clearly influences body image,^{7 8} the conscious body image may be only indirectly linked to primary sensory areas. Instead, body image is thought to predominately arise from the posterior parietal cortex (PPC) and to depend strongly on visual input. Phantom limb studies in amputees, for example, show that perceived movement of the phantom limb is associated with increased activity in PPC,²² and other non-painful phantom sensations are more linked to changes in PPC than SI.²³ Furthermore, in some cases, lesions in the PPC can suppress the experience of phantom limbs²⁴ and can induce asomatognosia, a condition in which parts of the body feel as though they have disappeared.^{25 26} Other studies have shown that the left PPC is involved with processing spatial information about bodies.^{27–29} Patients with damage to the left PPC can exhibit autotopagnosia, an inability to localise and orient different parts of the body while maintaining the ability to identify body parts.^{30 31} Despite cortical reorganisation of primary somatosensory areas, chronic sensorimotor loss may in fact not affect the body image as higher level areas such as the PPC are generally unaltered following SCI. Indeed, a patient with total large fibre deafferentation below the neck was assumed to rely on a (visual) body image to compensate for the complete absence of proprioceptive or body schema input.³²

Our BIT results show two clear directional effects. First, limb based body aspect ratios were systematically underestimated in all participants, suggesting that body image represents a broader, shorter shape than the physical body. Second, our results showed a relative elongation of the body image in SCI patients. These directional effects recall recent studies of the internal representations of the hand, which revealed a systematic directional distortion of the hand being perceived as broader and the fingers as shorter than their true shape.³³ Interestingly, these distortions appear to parallel the anisotropy of receptive field shape found in SI neurons, so may reflect a somatosensory frame of reference for the internal body model. Anaesthetising body parts results in acute increases in perceived size, particularly in increased width.^{7 8} Our results suggest that

these same distortions may apply to the image of the body as a whole: in all groups we found that arm length/shoulder width ratios and leg length/hip width ratios from the body image were less than the corresponding ratios measured from the body itself—that is, bodies are represented as wider relative to limb length than they really are. However, contrary to previous reports of wider perceived shoulder width in SCI patients than CTL,^{16 17} our implicit task found a subjective *elongation* effect in SCI patients. This suggests that the typical widening distortion is reduced in patients with SCI relative to CTL. These widening distortions might be expected on the basis of somatosensory information³³ but are not consistent with a body image derived from visual sources such as viewing one's own body directly or via a mirror, or from viewing others' bodies. After prolonged sensorimotor loss, the visual contribution to the body image may be increased relative to the somatosensory contribution, leading to reduction of the somatosensory based distortions that characterise normal internal models of the body.

Importantly, we found that lesion level in SCI patients did not predict which specific body parts were perceived as elongated. This could reflect a fundamental limitation of sensorimotor loss as an explanation for our results. One possibility is that the conscious body image may depend less on local sensorimotor traffic with individual body parts and more on the general experience of mobility and body posture as a whole—all of our patients were wheelchair users, despite a range of lesion levels. Alternatively, the combination of visual and somatosensory information that produces the body image may be organised for the body as a coherent whole, rather than separately for each body part. In this context, it would be interesting in future studies to measure the internal body model before and after interventions affecting only a single body part, such as anaesthesia.

The changes we observed in body image following SCI may be attributed to several different causes, or indeed to a mixture of causes. First, the absence of any effect of lesion level suggests that disruption of sensorimotor traffic from the body to the brain and vice versa is not a plausible explanation. In addition, our results cannot be explained by general distortions in the ability to perceive bodies, or to recognise one's own body shape, as both patient groups performed comparably with the CTL group on an explicit body template selection task. The body templates used in the template matching task varied in relative width and therefore were specifically relevant for testing for explicit distortions in body aspect ratios; none was revealed. When tested with the more implicit BIT, however, distortions in body aspect ratios were observed in SCI patients.

We propose two possible explanations for the changes in body image following SCI, one based on motor habits and the other based on visual perspective. On the first interpretation, sustained changes in body posture, possibly related to wheelchair use, might result in a changed body image. SCI patients typically undergo extensive rehabilitation to slowly adapt to their new body state. Patients are generally in a seated or laying position and must integrate these new postures and devices into their daily lives. A seated posture drastically changes the position of the body's centre of mass. The BIT, in contrast, requires estimating positions of body parts in a standing posture. The mismatch between the actual distribution of body parts relative to the centre of mass and that implied by the BIT may result in a vertical elongation. Another consequence of altered motor habits that may influence body image is the potential integration between a patient's body and a

wheelchair. Tools can be incorporated into a user's peripersonal space,³⁴ and tool use can alter body representations.^{35 36} In the specific context of wheelchair use, one recent review³⁷ discussed the notion that acquiring wheelchair skills results in patients altering their body representation and embodying the device. Physical and emotional adjustments that follow wheelchair confinement could result in a new body representation in which the person's physical self, as well as their feelings and actions, incorporate the wheelchair.³⁸ As reported anecdotally, prolonged wheelchair use and the reconstruction of one's capabilities results in the chair becoming part of a person's body representation: "[the chair] is a part of me. It's my other half. My mind is one half, the wheelchair is my body".³⁹ Indeed, Arnhoff and Mehl¹⁶ suggested that the subjective broadening of the shoulders they identified in SCI patients could reflect referencing the body width to the width of the wheelchair. It is possible that the changes in body image we saw across our PPP and TPP may in part reflect the embodiment of a wheelchair into their body representations. Specifically, our data suggest that confinement to a seated posture, and possibly embodiment of a wheelchair, may result in an elongated image of the body and limbs relative to body width. However, a causal link has not been established, and it remains unclear why these changes in motor habits cause changes in the *vertical* dimension of the body image in particular, rather than other dimensions or all dimensions.

A second possible explanation of our results invokes visual perspective. The observed elongation in SCI patients may seem paradoxical, given that a seated person has a lower overall height than the same person standing. However, being confined to a seated position may result in overcompensation of height when patients are required to imagine themselves standing. Most people recognise the childhood experience of adults seeming tall in comparison with one's own, lesser height. For the SCI patient, their own standing body image would show a similar contrast effect relative to their actual body posture. It would be interesting in future work to test whether the implicit perception of increased body and limb length relative to width is still observed if patients respond by locating body parts relative to an image of their seated, rather than their standing, body. However, visuospatial perspective makes use of a seated canonical posture problematic: for example, the knee and hip of a seated person are very close when projected onto a two-dimensional screen. In addition, an explanation based on visual perspective would predict elongation of the image of *others'* bodies, as well as one's own. This prediction might also be tested in future research.

In summary, the present results cannot yet conclusively identify the cause of the distorted body image in SCI. In the meantime, we suggest that the altered posture and altered visual experience might both be involved.

The BIT gives a quantitative measure of distortions of conscious body image. In addition to this body image, we are thought to also have a more unconscious body model, the body schema, which reflects more what the body is 'felt' to be like as opposed to what it is 'perceived' to be like.¹ One would predict that in SCI patients the body schema, which is thought to rely more on proprioceptive and tactile inputs as opposed to visual, would be considerably distorted. There is also evidence of a lexical-semantic representation of the body, which is impaired in certain stroke patients.⁴⁰ The ability of SCI patients to perform the BIT and their unimpaired performance on the template selection task suggest that lexical-semantic knowledge of their bodies remains intact.

One potential limitation of our study is that our TPP were not completely without upper body motor function. All TPP, however, had significant sensory loss in their arms and below their shoulders relative to the PPP (table 1). Furthermore, when only patients with AIS grade A lesions were analysed, we still found that patients had elongated body aspect ratios relative to the CTL group. Crucially, this TPP group allowed us to control for average body posture and device use across our patient groups, as all patients were confined to wheelchairs. Future studies might explore the body image in TPP with complete sensorimotor loss who are unable to use manual wheelchairs. It may also be interesting to test responses to an image with a lying position on the screen compared with a standing position, which from a test perspective would provide a comparable two-dimensional image.

Chronic sensorimotor loss following SCI, and the subsequent presumed cortical reorganisation, may not directly affect body image, as changes were not related to the level of injury. Instead, it is possible that changes in how the body is used and experienced on a daily basis may alter one's body image. This provides new knowledge of what information is used to form body representations. Understanding changes in perceived body dimensions may also be important for training SCI patients to move within the spatial constraints of their environment, particularly when dangerous objects are present. For example, many SCI patients have somatosensory loss, and so do not receive sensory signals about contact with environmental objects. They may therefore rely on a representation of body size and shape to avoid dangerous objects in the environment. If this representation is distorted, then navigating obstacles in the environment may be impaired. Therefore, rehabilitation of a distorted body image may improve navigation and interaction with the environment, and may reduce dangerous interactions with environmental objects, such as bumps and burns. Finally, the ability to measure body image quantitatively with the BIT may also be useful in assessing the effects of body image interventions, and in assessing changes in body image as a result of training with prosthetic devices and virtual environments.

Acknowledgements We would like to thank Salvatore Aglioti for feedback on the experimental design.

Contributors All authors contributed to the design of the experiment. CTF, MP and GS collected the data. CTF analysed the data. CTF, MP, MRL and PH contributed to the writing and editing of the manuscript.

Funding This work was supported by Integrated Project grant No 257695, EU FP7-ICT-2009-5 to PH and a grant from the International Foundation for Research in Paraplegia (P133) to MP.

Competing interests None.

Ethics approval The study was approved by the ethics committee of Santa Lucia Hospital, Rome, Italy.

Provenance and peer review Not commissioned; externally peer reviewed.

REFERENCES

- Longo MR, Azañon E, Haggard P. More than skin deep: body representation beyond primary somatosensory cortex. *Neuropsychologia* 2010;**48**:655–68.
- Schilder P. *The image and appearance of the human body*. New York: International Universities, 1935.
- Bors E. Phantom limbs of patients with spinal cord injury. *AMA Arch Neurol Psychiatry* 1951;**66**:610–31.
- Conomy JP. Disorders of body image after spinal cord injury. *Neurology* 1973;**23**:842–50.
- Evans JH. On disturbance of the body image in paraplegia. *Brain* 1962;**85**:687–700.
- Melzack R, Bromage PR. Experimental phantom limbs. *Exp Neurol* 1973;**39**:261–9.
- Gandevia SC, Phegan CM. Perceptual distortions of the human body image produced by local anaesthesia, pain and cutaneous stimulation. *J Physiol* 1999;**514**:609–16.
- Paqueron X, Leguen M, Rosenthal D, et al. The phenomenology of body image distortions induced by regional anaesthesia. *Brain* 2003;**126**:702–12.
- Henderson WR, Smyth G. Phantom limbs. *J Neurol Neurosurg Psychiatry* 1948;**11**:88–112.
- Ramachandran VS, Hirstein W. The perception of phantom limbs. The D. O. Hebb lecture. *Brain* 1998;**121**:1603–30.
- Bruehlmeier M, Dietz V, Leenders KL, et al. How does the human brain deal with a spinal cord injury? *Eur J Neurosci* 1998;**10**:3918–22.
- Freund P, Weiskopf N, Ward NS, et al. Disability, atrophy and cortical reorganization following spinal cord injury. *Brain* 2011;**134**:1610–22.
- Henderson LA, Gustin SM, Macey PM, et al. Functional reorganization of the brain in humans following spinal cord injury: evidence for underlying changes in cortical anatomy. *J Neurosci* 2011;**31**:2630–7.
- Moore CI, Stern CE, Dunbar C, et al. Referred phantom sensations and cortical reorganization after spinal cord injury in humans. *Proc Natl Acad Sci USA* 2000;**97**:14703–8.
- Wrigley PJ, Press SR, Gustin SM, et al. Neuropathic pain and primary somatosensory cortex reorganization following spinal cord injury. *Pain* 2009;**141**:52–9.
- Arnhoff FN, Mehl MC. Body image deterioration in paraplegia. *J Nerv Ment Dis* 1963;**137**:88–92.
- Stensman R. Body image among 22 persons with acquired and congenital severe mobility impairment. *Paraplegia* 1989;**27**:27–35.
- Marino RJ, Barros T, Biering-Sorensen F, et al. International standards for neurological classification of spinal cord injury. *J Spinal Cord Med* 2003;**26**(Suppl 1):S50–6.
- Daurat-Hmeljjak C, Stambak M, Berges J. *Il test dello schema corporeo*. Una prova di conoscenza e costruzione dell'immagine del corpo. Firenze: Organizzazioni Speciali, 1978.
- Bookstein FL. *Morphometric tools for landmark data: geometry and biology*. Cambridge: Cambridge University Press, 1991.
- Pons TP, Garraghty PE, Ommaya AK, et al. Massive cortical reorganization after sensory deafferentation in adult macaques. *Science* 1991;**252**:1857–60.
- Kew JJ, Ridding MC, Rothwell JC, et al. Reorganization of cortical blood flow and transcranial magnetic stimulation maps in human subjects after upper limb amputation. *J Neurophysiol* 1994;**72**:2517–24.
- Flor H, Muhlnickel W, Karl A, et al. A neural substrate for nonpainful phantom limb phenomena. *Neuroreport* 2000;**11**:1407–11.
- Melzack R. Phantom limbs. *Sci Am* 1992;**266**:120–6.
- Salanova V, Andermann F, Rasmussen T, et al. Parietal lobe epilepsy. Clinical manifestations and outcome in 82 patients treated surgically between 1929 and 1988. *Brain* 1995;**118**:607–27.
- Wolpert DM, Goodbody SJ, Husain M. Maintaining internal representations: the role of the human superior parietal lobe. *Nat Neurosci* 1998;**1**:529–33.
- Corradi-Dell'Acqua C, Hesse MD, Rumiati RI, et al. Where is a nose with respect to a foot? The left posterior parietal cortex processes spatial relationships among body parts. *Cereb Cortex* 2008;**18**:2879–90.
- Corradi-Dell'Acqua C, Tomasino B, Fink GR. What is the position of an arm relative to the body? Neural correlates of body schema and body structural description. *J Neurosci* 2009;**29**:4162–71.
- Felician O, Anton JL, Nazarian B, et al. Where is your shoulder? Neural correlates of localizing others' body parts. *Neuropsychologia* 2009;**47**:1909–16.
- Buxbaum LJ, Coslett HB. Specialised structural descriptions for human body parts: Evidence from autotopagnosia. *Cogn Neuropsychol* 2001;**18**:289–306.
- Pick A. Störung der Orientierung am eigenen Körper. *Psychol Forshung* 1922;**2**:303–18.
- Gallagher S, Cole J. Body schema and body image in a deafferented subject. *J Mind Behav* 1995;**16**:369–90.
- Longo MR, Haggard P. An implicit body representation underlying human position sense. *Proc Natl Acad Sci USA* 2010;**107**:11727–32.
- Loeuire SF, Longo MR. The plasticity of near space: evidence for contraction. *Cognition* 2009;**112**:451–6.
- Cardinali L, Jacobs S, Brozzoli C, et al. Grab an object with a tool and change your body: tool-use-dependent changes of body representation for action. *Exp Brain Res* 2012.
- Cardinali L, Frassinetti F, Brozzoli C, et al. Tool-use induces morphological updating of the body schema. *Curr Biol* 2009;**19**:R478–9.
- Standal OF. Re-embodiment: incorporation through embodied learning of wheelchair skills. *Med Health Care Philos* 2011;**14**:177–84.
- Winance M. Trying out the wheelchair: the mutual shaping of people and devices through adjustment. *Sci Technol Human Values* 2006;**31**:52–72.
- Papadimitriou C. Becoming en-wheeled: the situated accomplishment of re-embodiment as a wheelchair user after spinal cord injury. *Disabil Society* 2008;**23**:691–704.
- Schwoebel J, Coslett HB. Evidence for multiple, distinct representations of the human body. *J Cogn Neurosci* 2005;**17**:543–53.